

INTRODUCTION

Children's oral health is predictably influenced by including Social Determinants of Health (SDoH). The lack of health guidance and monitoring of oral health results in negative outcomes such as tooth decay, oral infections, late identification of dental developmental problems, chronic infections, developmental delays, the associated costs, and harm to Quality of Life. This poster highlights the need for improved engagement between healthcare payers and consumers to facilitate timely oral health monitoring.

ABSTRACT

This report describes the observation of a 10 year old child in foster care with a severely ankylosed primary molar. Despite recommendations for a consultation and treatment plan, the patient missed several appointments due to poor communication and inadequate documentation in the patient's record. The mouth is a predictable place. Timely dental visits and communication with guardians are crucial to reduce the risk of future dental problems and improve patients' quality of life. The result of this situation is leading to a worsening of the impact of the primary tooth ankylosis. The delay in appropriate timely management of this developmental concern is a predictable sequence of Social Determinants of Health.

CASE REPORT

A 10 y/o female patient presents with grandmother with no complaints

Medical history:

- 10-year-old foster child with ADHD taking Vyvanse

Social history:

- Legal guardian is the child's grandmother
- No documented dental appointments until October 2020, despite claims of annual visits

Dental history:

- Initial dental visit without complaints
- Panoramic radiograph revealed an unerupted upper left second primary molar (#J)
- Recommendation for orthodontic and oral surgery consultation and treatment plan
- Missed several appointments due to inadequate documentation and poor communication with legal guardian
- Tooth remained unerupted and prompted another consultation

Clinical exam:

- Upper left second primary molar not clinically visible

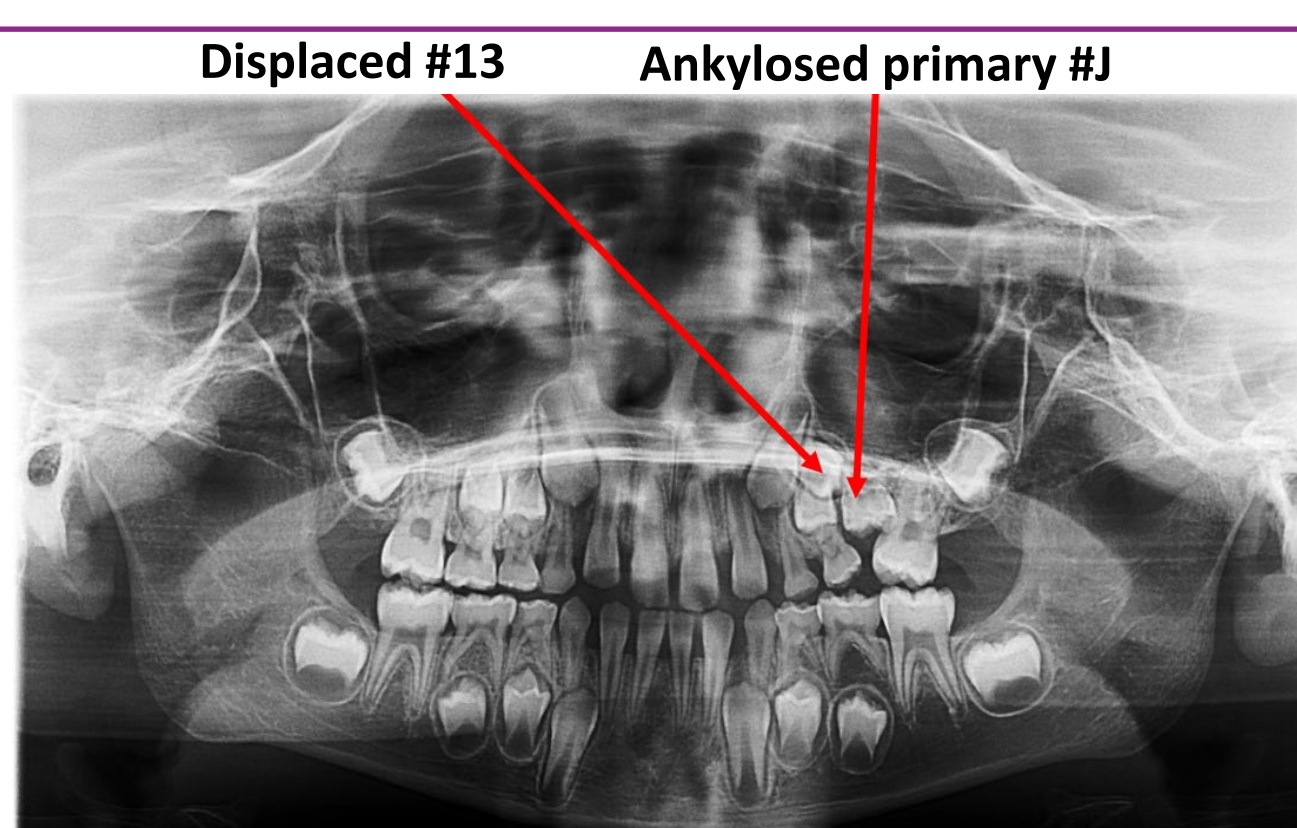
Radiographic exam:

- Panoramic radiograph revealed unerupted #J

Diagnosis:

- Severely ankylosed primary molar (#J) with severe displacement of #13

FIGURE 1: PANORAMIC RADIOGRAPH IN 2020



CASE MANAGEMENT

DESIRED TIMELY PARTNERSHIP

VS

OBSERVED-LATE ENGAGEMENT

Visit 1: Age 3-6 or before first molar is present

- Identification of late primary dentition
- #J erupted or occluded or submerged
- Appliance → consider distal shoe

Late identification of mixed dentition of severely ankylosed #J with severely displaced #13

Case Management:

- Oral surgery needed
- Orthodontist needed with more complex treatment
- Sedation needed
- Visit to monitor progress

Case Management: after first molar is present

- Identification and possible extraction of #J with space regaining appliance
- Nance of space regaining appliance of #14
- Observe eruption of #13
- Active guidance of #13 using orthodontics
- Appliance or final outcome position of #13

SDoH Concerns:

- Compliance with far more visits
- Caries risk of ortho appliance
- Timely visits
- Aesthetics of orthodontic treatment

SDoH Concerns:

Compliance with timely visits

Tentative Cost:

- Comprehensive exam: \$75
- Panoramic radiograph: \$100
- 2 Bitewings: \$25
- Simple extraction: \$100
- Space Maintainer: \$250

Total: \$550

Tentative Cost:

- Comprehensive exam: \$75
- Panoramic radiograph: \$100
- CBCT: \$280
- 4 bitewings: \$50
- OS Consult: \$150
- Ortho consult: \$150
- IV sedation \$400
- Surgical extraction: \$175
- Palatal Expander: \$400
- Comprehensive Orthodontic tx: \$3,000

Total: \$4,780

CASE SIGNIFICANCE

The prevalence of primary molar ankylosis is 2%-11%. This case highlights the need for improved engagement between healthcare payers and consumers to facilitate timely oral health monitoring. The lack of timely health guidance and monitoring of oral health results in negative outcomes, such as chronic infections, developmental delays, increased costs, reduced quality of life, and poor Quality of Life outcomes. The case also underscores the importance of proper documentation, particularly in cases involving legal guardianship.